



IMAGES IN
NEUROCRITICAL CARE

Diffuse cerebral microbleeds in a patient with HIV and disseminated intravascular coagulation

Wonjae Sung, MD, MSc; Hyun-Seung Gwak, MD; Young Seo Kim, MD, PhD

Department of Neurology, Hanyang University College of Medicine, Seoul, Korea

Received: October 24, 2022

Revised: November 02, 2022

Accepted: November 21, 2022

Corresponding Author:

Young Seo Kim, MD, PhD

Department of Neurology, Hanyang University College of Medicine, 222-1 Wangsimni-ro, Seongdong-gu, Seoul 04763, Korea

Tel: +82-2290-8375

Fax: +82-2-2296-8370

E-mail: kimys1@hanyang.ac.kr

Hypoxemia and critical illnesses such as sepsis and disseminated intravascular coagulopathy (DIC) are possible causes of massive microbleeds in the brain parenchyma [1]. We report a patient with human immunodeficiency virus (HIV) showing extensive

cerebral microbleeds. A 59-year-old male patient presented with generalized tonic-clonic seizures. After admission, he was diagnosed with HIV infection while evaluating for pneumonia. Ten days after antiretroviral therapy (ART), DIC occurred as a result

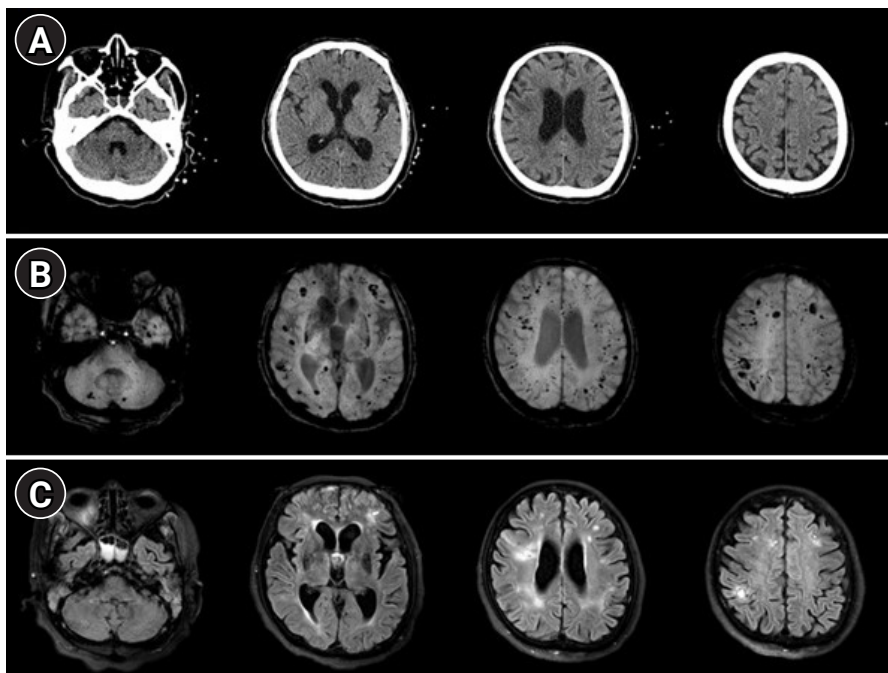


Fig. 1. Computed tomography (CT), susceptibility-weighted image (SWI), and fluid-attenuated inversion recovery (FLAIR) images in magnetic resonance imaging of the brain. (A) CT images demonstrate no definite evidence of intracranial hemorrhage. (B) However, SWI presents with multiple hypointensities in the bilateral cerebral hemisphere cerebellum, predominant at the gray and white matter junction, suggestive of microbleeds. (C) FLAIR images show multiple hyperintense lesions involving cerebral cortices and white matter in regions with large microbleeds on SWI.

of pneumonia progression, compatible with immune reconstitution inflammatory syndrome (IRIS). Blood analysis showed elevated D-dimer levels (1,750 ng/mL), prolonged prothrombin time (16.1 seconds), and low platelet count ($63 \times 10^3/\mu\text{L}$). He was stuporous with normal brainstem signs of brainstem injury. While the patient's brain computed tomography images were unremarkable (Fig. 1A), susceptibility-weighted images demonstrated innumerable hypointense foci in the cerebrum and cerebellum suggestive of microbleeds (Fig. 1B). Multifocal hyperintense lesions were also observed in the fluid-attenuated inversion recovery images, which could induce a symptomatic seizure (Fig. 1C). Meanwhile, the cerebrospinal fluid examination was within the normal range. Anti-epileptic drugs were administered, and the patient's mental status improved from stuporous to alert.

Thus, IRIS triggered by ART initiation can affect the central nervous system in patients with HIV [2]. Therefore, clinicians should consider brain involvement presenting as extensive microbleeds in critically ill HIV patient.

ARTICLE INFORMATION

Ethics statement

This case was reviewed and approved by the Institutional Review Board of Hanyang University Seoul Hospital (No. HY 2022-10-034). The need for informed consent was waived by the Board.

Conflict of interest

No potential conflict of interest relevant to this article.

ORCID

Wonjae Sung <https://orcid.org/0000-0002-4637-5890>
 Hyun-Seung Gwak <https://orcid.org/0000-0001-6743-9315>
 Young Seo Kim <https://orcid.org/0000-0002-7050-3426>

Author contributions

Conceptualization: HSG, YSK. Data curation: HSG, WS. Formal analysis: HSG, WS. Methodology: HSG, YSK. Project administration: WS. Visualization: WS, YSK. Writing—original draft: all authors. Writing—review & editing: WS, YSK.

REFERENCES

1. Valenti-Azcarate R, Irimia Sieira P, Esparragosa Vazquez I, Riverol Fernandez M. Multiple cerebral microbleeds associated with disseminated intravascular coagulation. *Neurologia (Engl Ed)* 2021;36:88-9.
2. Johnson T, Nath A. Neurological complications of immune reconstitution in HIV-infected populations. *Ann N Y Acad Sci* 2010;1184:106-20.