BRIEF COMMUNICATION
J Neurocrit Care 2014;7(2):145
ISSN 2005-0348

Brain Calcification Associated with Pseudohypoparathyroidism

Hyunjin Kim, MD[1], H. Alex Choi, MD, MS[2], Kiwon Lee, MD[2], and Sang-Beom Jeon, MD, PhD[1]

[1]Department of Neurology, Asan Medical Center, University of Ulsan College of Medicine, Seoul, Korea
[2]Departments of Neurology and Neurosurgery, The University of Texas Medical School at Houston, Houston, TX , USA

A 23-year-old, previously healthy woman presented with a first-onset generalized tonic-clonic seizure. Neurological examination was unremarkable. Computed tomography of the brain showed extensive symmetric calcifications in the corticomedullary junctions, basal ganglia, thalami, and cerebellar hemispheres (Fig. 1). Serum laboratory studies revealed levels of calcium 5.7 mg/dL (8.6-10.2 mg/dL), phosphorus 4.4 mg/dL (3.5-4.5 mg/dL), and parathyroid hormone 151 pg/mL (10-65 pg/mL) consistent with pseudohypoparathyroidism. Her clinical features of a round face, short stature, and short fourth and fifth metacarpals suggested pseudohypoparathyroidism type Ia, Albright's hereditary osteodystrophy.[1] Pseudohypoparathyroidism is one of medical conditions which can be accompanied by brain calcifications, especially strio-pallido-dentate calcinosis.[2]

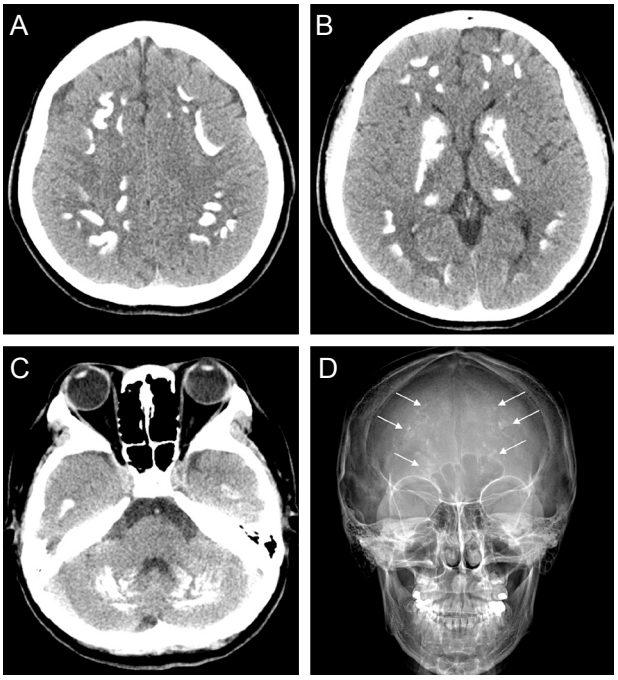

Figure 1. Brain CT demonstrates extensive symmetric calcifications in corticomedullary junctions (A), basal ganglia and thalami (B), and cerebellar hemispheres (C). Calcifications of the brain are also seen in a cranial radiograph (D). Arrows indicate calcifications.

REFERENCES

1. Al-Azem H, Khan AA. Hypoparathyroidism. *Best Pract Res Clin Endocrinol Metab* 2012;26:517-22.
2. Bonazza S, La Morgia C, Martinelli P, Capellari S. Strio-pallido-dentate calcinosis: a diagnostic approach in adult patients. *Neurol Sci* 2011;32:537-45.

Received: November 16, 2014 / **Revised:** November 18, 2014
Accepted: November 18, 2014
Address for correspondence: Sang-Beom Jeon, MD, PhD
Department of Neurology, Asan Medical Center, University of Ulsan College of Medicine, 88 Olympic-ro 43-gil, Songpa-gu, Seoul 138-736, Korea
Tel: +82-2-3010-3440, Fax: +82-2-474-4691
E-mail: sbjeonmd@gmail.com

Copyright © 2014 The Korean Neurocritical Care Society